

The Potential Value of EGFR and P53 Immunostaining in Tumors of the Urinary Bladder

Ibrahim N¹, Elzagheid A², El-Hashmi H¹, Syrjänen K³ and Alhakim S⁴

1 Departments of Pathology and Surgery, African Oncology Institute, Sabratha, Libya, **2** Department of Pathology, Faculty of Medicine, Al-Arab Medical University, Benghazi, Libya, **3** Department of Oncology and Radiotherapy, Turku University Hospital, Savitehtaankatu, Turku, Finland and **4** Department of Pathology, National Cancer Institute, Cairo, Egypt.

Abstract; The expression of EGFR and p53 has not been adequately studied as a prognostic tool in urinary bladder tumors. We analyzed 74 bladder cancer samples from Egypt for EGFR and p53 expression using immunohistochemistry. The tumors were of different histological types, grades and clinical stages, and with established lymph node status. Almost 61% of the tumors showed positive membranous EGFR expression and 74.3% had positive nuclear staining of p53. Analysis of correlation of the IHC staining with clinical variables showed a significant correlation only between EGFR expression and histological type ($p=0.002$, ANOVA), in that the expression was higher in squamous cell carcinomas than in other histological types. There were no significant correlations between p53 or EGFR with the other clinicopathological variables, including age, sex, staging, grading, and lymph node status. Further studies are needed to determine if EGFR and p53 might be used as prognostic tools in bladder cancer.

Key words: *Bladder cancer, p53, EGFR, Immunohistochemistry, Clinical data.*

Introduction

Bladder cancer is a moderately prevalent disease, with 10,200 new cases and 5,000 annual deaths occurring in the UK alone [1]. Prognosis depends on tumor stage and grade; higher stage, muscle-invading tumors have poorer prognosis. The results of radical surgery in patients with lower stage disease are remarkable [2], but the overall five-year survival following radical treatment for tumors of all stages remains about 40-50% [3].

Epidermal growth factor receptor (EGFR, also known as ErbB1) is a member of the ErbB family of receptors, which are important for relaying signals that regulate cell proliferation, differentiation, motility and apoptosis. The other family members are ErbB2, ErbB3 and ErbB4. EGFR is a 170-kDa trans-membrane protein that exhibits intrinsic tyrosine kinase activity when it binds one of its cognate ligands [4,5]. Activation of EGFR leads to a wide variety of biological responses, such as proliferation, differentiation, migration, modulation of apoptosis, invasion, and metastasis, and under pathophysiological conditions it contributes to progression of different malignancies [6,7,8]. Thus, strong expression of EGFR appears to be a negative prognostic factor in several human malignancies, including breast and bladder cancer [9,10], which prompted us to select EGFR as the first marker to be tested.

Another key protein in human carcinogenesis is the tumor suppressor p53. Mutation in the wild type p53 gene and nuclear accumulation of non-functional p53 protein reflect compensatory over-expression of the protein [11]. p53 is a nuclear phosphoprotein functioning as a transcription factor. It regulates cell growth indirectly and inhibits cells with mutagenic breaks in the DNA from entering the S-phase by arresting the cell cycle in G1. The mutant p53 also has a longer half-life. Therefore, nuclear p53 protein accumulation is a common phenomenon in many human malignancies [12-14], and for that reason we selected it as a second marker in this study.

Material and methods

Tumor samples; We obtained samples of primary tumors of the urinary bladder from 74 patients ranging in age from 7 to 81 years. Fifty-five of the patients (74.3%) were males. The material was provided by the National Cancer Institute, Cairo (Egypt) as paraffin blocks. The key clinical data of the patients and their tumors are shown in Table 1.

EGFR and p53 immunostaining

From each sample we prepared one hematoxylin and eosin section and two unstained 5- μ m sections for immunohistochemistry (IHC). IHC staining was done at the Department of Pathology, African Institute of Oncology, Sabratha, Libya.

An experienced pathologist (SA) confirmed all histological diagnoses. IHC analysis was done using the automatic system (BenchMark XT, Ventana Medical Systems, Inc. Tucson, Arizona, USA). This fully automated processing of bar code-labeled slides included baking of the slides, solvent free deparaffinization, antigen retrieval in a cell conditioning buffer CC2 (mild: 36 min conditioning, and standard: 60 min conditioning), and incubation with the monoclonal anti-EGFR antibody (clone 3C6, Ventana Medical Systems, Inc. Tucson, Arizona, USA), (32 min, 37°C). The same protocol was followed for staining with the monoclonal anti-p53 antibody (clone Do7, Ventana Medical Systems, Inc. Tucson, Arizona, USA). For detection we used UltraView™ Universal DAB, a biotin-free, multimer-based detection system for specific and sensitive detection of mouse IgG, mouse IgM, and rabbit IgG primary antibodies. UltraView DAB includes UltraView Universal HRP, UltraView Universal DAB Inhibitor, UltraView Universal DAB Chromogen, UltraView Universal DAB H2O2, and UltraView Universal DAB Copper. Counterstaining was with hematoxylin (2021) for 4 min, and post-counterstaining was with bluing reagent (2037) for 4 min. After staining, the sections were dehydrated in ethanol, cleared in xylene, and covered with Mountex and cover slips.

Evaluation of EGFR staining

The EGFR staining was evaluated by an observer blinded to the clinical data (AE) using regular light microscopy (Leitz, Laborlux K, Leitz Portugal). Only membranous staining was evaluated and scored (+++, ++, +, -) [15]. In calculating the staining index known as membrane index (MI), both the intensity of the staining and the fraction of positively-stained cells were taken into account, using the following formula [16].

$$I = 0 * f_0 + 1 * f_1 + 2 * f_2 + 3 * f_3$$

Here I is the staining index, and f₀-f₃ represents the fraction of the cells showing a defined level of staining intensity (from 0 to 3). Theoretically, the index ranges from 0 to 3 [16].

Evaluation of p53 staining

The nuclear staining of p53 was evaluated in a high intensity area by estimating the fraction of positive nuclei among 200 nuclei. Before analyzing the staining results, a few samples were analyzed twice by AE and once by NI to estimate intra- and inter-observer reproducibility. This was shown to be excellent for both EGFR and p53 immunostaining ($\kappa=0.782$ and $\kappa=0.832$, respectively).

Statistical analysis

SPSS for Windows (16.0.2 SPSS, Inc. Chicago, Illinois, USA) was used for statistical analysis. Frequency tables were analyzed using the Chi-square test or Fisher's exact test (where appropriate) with Pearson's R or likelihood ratio (LR) statistics to assess the significance of the correlation between categorical variables. Differences in the means of continuous variables between the groups were analyzed using ANOVA (analysis of variance), or non-parametric tests (Mann-Whitney, Kruskal-Wallis) tests. In all analyses, $p < 0.05$ was regarded as significant.

Results

EGFR and p53 expression patterns are illustrated in Figure 1. The expression pattern of EGFR was predominantly membranous. Forty-five samples (60.8%) showed positive membranous EGFR expression, whereas no expression was observed in 21 samples (28.3%) and 8 samples (10.8%) could not be evaluated. Fifty-five samples (74.3%) showed positive nuclear staining of p53, whereas 11 samples (14.8%) were negative and 8 (10.8%) were not adequately stained.

We analyzed EGFR and p53 expression in relation to all available clinical variables and tumor characteristics by univariate analysis. The clinical variables recorded were age, sex, grading, staging, lymph node status, and histological type. A significant correlation between EGFR expression and histological type was observed ($p=0.002$, ANOVA). EGFR expression was higher in squamous cell carcinomas than in the other types of urinary bladder tumors. We did not observe any other significant correlations between p53 or EGFR expression on the one hand and the other clinicopathological variables on the other hand.

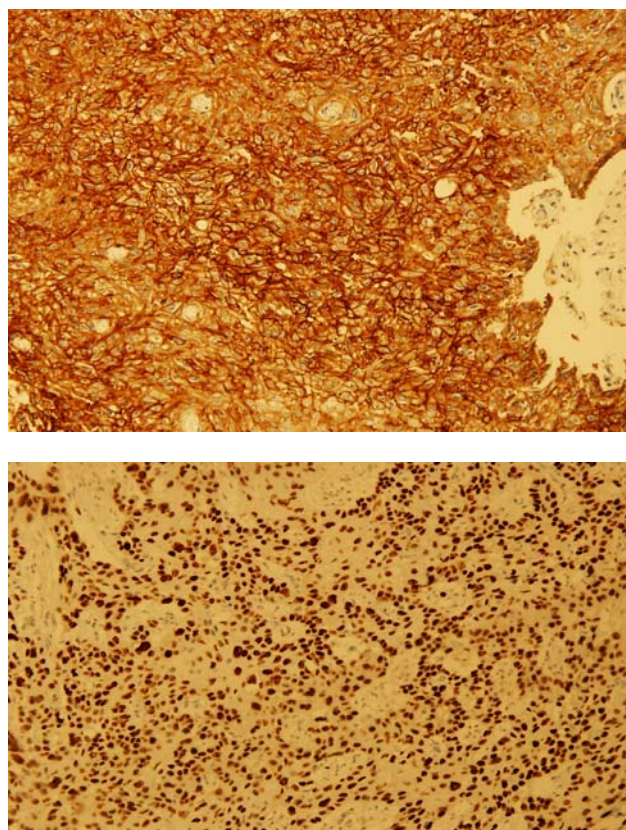


Figure 1 Immunohistochemical staining of tumor of urinary bladder. (a) Membranous expression of EGFR. (b) Nuclear expression of p53 (x20 magnification)

Table 1 Key characteristics of the tumors

Variable	No. or value	Percent *
Primary nodal status		
NO	33	44.6
N+	17	22.9
Nx	24	32.4
Histological grade		
I	6	8.1
II	27	36.5
III	24	32.4
Not available	17	22.9
Stage		
II	15	20.2
III	13	17.6
IV	6	8.1
Not available	40	54.0
Histological type		
Squamous carcinoma	20	27.0
Transitional carcinoma	17	22.9
Adenocarcinoma	13	17.5
Undifferentiated	6	8.1
Others [#]	17	22.9
Unclassified	1	1.3

*When applicable; Nx, unknown; NA, not available. [#]Spindle cell tumor, leiomyosarcoma, sarcomatoid tumor, embryonal rhabdomyoma.

Discussion

Activation of proto-oncogenes and inactivation of tumor suppressor genes are frequently involved in tumorigenesis. Among other things, proto-oncogenes control normal cell growth pathways and cell cycle regulation. Once proto-oncogenes undergo mutations, rearrangements, insertions, or amplification, they can activate genes (oncogenes) and result in uncontrolled cellular proliferation [17]. Different classes of oncoproteins have

been characterized at the molecular level, including growth factors, growth factor receptors and transcriptional factors.

In a series of 52 small-cell carcinomas of the bladder, expression of EGFR in the neoplastic cells was reported to have a mixed membranous and cytoplasmic pattern [18]. In our current study, the expression EGFR was only membranous in all cancer samples. In their study, Wang et al. [18] reported that positive IHC expression of EGFR was observed in bladder tumors of 14/52 patients (27%): 7 with 10% to 25% staining, 4 with 25% to 50% staining, 1 with 50% to 75% staining, and 2 with 75% to 100% staining. In the present series, membranous expression or accumulation was observed in 60.8% (45 cases) of the tumor specimens, whereas 21 cases (28.3%) were negative and 8 cases (10.8%) were not evaluable because the tissue became detached after staining. This difference, i.e. lack of cytoplasmic expression in our study, might be due to technical factors. It is well known that different antibodies can give different staining patterns, and furthermore, interpretation of cytoplasmic expression is more subjective than membranous pattern, though the pictures published by Wang et al. [18] are quite convincing in this respect. The difference might also be due to the use of different target material. Small-cell carcinoma of the bladder is a distinct entity, and the expression profile in this type of lesion might be different from that of the usual histological types, of which the majority of cases in the present series consisted. All this makes a direct comparison between these two studies of limited value. Recently, another study was published comprising 16 cases of squamous cell carcinomas [19]. All 16 cases and 11/16 were positive for EGFR and p53, respectively. This is fully consonant with our observations, where squamous cell carcinomas expressed EGFR more often and more intensely than the other histological types. Also the staining pattern for EGFR was membranous in both of these studies and p53 was nuclear. However, we stress that in our series, squamous cell carcinomas represent a minority (27%) of all lesions.

We observed significant correlations only between EGFR expression and the histological type of the tumors, with squamous cell tumors showing more intense expression. None of the other recorded clinical variables had any significant association with EGFR, including age, sex, grade, lymph node status, and stage. This observation is in agreement with a report on small-cell carcinoma of the urinary bladder [18]. On the basis of this small study, it is clearly premature to draw definite conclusions about the practical implications of EGFR staining in bladder cancer. The distinct expression in different histological types might have some potential value in differential diagnosis of problem cases, but to confirm this, we need to analyze a substantially larger series of well characterized cases of different histological types of bladder tumors. However, our study does not provide any direct evidence that EGFR staining would be of value in disease prognostication.

The expression of p53 was nuclear in all tumor tissues, which confirms previous observations [12]. There was no correlation between p53 expression and any of the clinicopathologic characteristics recorded. Unfortunately, published data on p53 in bladder carcinomas are not

sufficient to enable direct comparisons [10]. However, in their study of 99 transitional cell carcinomas, Vardar et al [10] reported a difference in p53 over-expression between low-grade and high grade tumors ($p < 0.05$). There was no significant relationship for recurrence between p53-positive and p53-negative groups, but there was a statistically significant relationship between progression and histological grade of the tumors. Similarly, p53 had no significant relationship with tumor recurrences ($p > 0.05$), but its relationship with progression was statistically significant ($p < 0.05$). However, we could not confirm any of these observations in our study. At this stage, additional studies are clearly needed to cast further light on the possible value of p53 as a prognostic and predictive marker in bladder cancer.

To conclude, EGFR and p53 seem to be expressed in most bladder carcinomas, but some differences might exist in the expression of (at least) EGFR between the different histological types of these tumors. Further work might provide new insights that might help dividing the patients into subgroups with respect to their different management options.

References

1. Cancer Research UK, cancer. State monograph 2004.
2. Chang SS, Cookson MS, Baumgartner RG, Wells N, Smith JA Jr. Analysis of early complications after radical cystectomy: results of a collaborative care pathway. *J Urol.* 2002; 167:2010-16.
3. Stein JP, Leiskovsky G, Cote R, et al. Radical cystectomy in the treatment of invasive bladder cancer: long term results in 1,054 patients. *J. Clin. Oncol.* 2001; 19:666-75.
4. Ullric A, Coussens L, Hayflick JS, et al. Human epidermal growth factor receptor cDNA sequence and aberrant expression of the amplified gene in A431 epidermal cancer cells. *Nature* 1984; 309:418-25.
5. Carpenter G, Gohen S. Epidermal growth factor. *J Biol Chem.* 1990, 265:7709-12.
6. Kim TY, Han SW, Bang Yj. Chasing targets for EGFR tyrosine kinase inhibitors in non-small-cell lung cancer: Asian perspectives. *Expert Rev Mol Diagn.* 2007; 6:821-36.
7. Schiff BA, McMurphy AB, Jasser SA, et al. Epidermal Growth Factor Receptor (EGFR) Is Overexpressed in Anaplastic Thyroid Cancer, and the EGFR Inhibitor Gefitinib Inhibits the Growth of Anaplastic Thyroid Cancer. *Clinical Cancer Research.* 2004; 10:8594-8602.
8. Standberg AA. Cytogenetics and molecular genetics of bladder cancer: a personal view. *Am J Med Genet.* 2002; 115:173-82.
9. Nicholson S, Richard J, Sainsbury C, et al. Epidermal Growth factor receptor (EGFR) results of a 6 year follow-up study in operable breast cancer with emphasis on the node negative subgroup. *Br J Cancer.* 1991; 63:146-50.
10. Lipponen P, Eskelinen M. Expression of epidermal growth factor receptor in bladder cancer as related to established prognostic factors, oncoprotein (c-erbB-2, p53) expression and long-term prognosis. *Br J Cancer.* 1994; 69:1120-5.
11. Jia L, Liu Y, Yi X, Miron A, Crum CP, Kong B, Zheng W. Endometrial glandular dysplasia with frequent p53 gene mutation: a genetic evidence supporting its precancer nature for endometrial serous carcinoma. *Clin Cancer Res.* 2008; 14:2263-9.
12. Vardar E, Gunlusoy B, Minareci S, Postaci H, Ayder AR. Evaluation of p53 nuclear accumulation in low- and high-grade (WHO/ISUP classification) transitional papillary carcinomas of the bladder for tumor recurrence and progression. *Urol Int.* 2006; 77:27-33.
13. Hollstein M, Sidransky D, Vogelstein B, Harris CC. p53 mutations in human cancer. *Science.* 1991; 253:49-53.
14. Hollstein M, Shomer B, Greenblatt M, et al. Somatic point mutations in the p53 gene of human tumors and cell lines: updated compilation. *Nucleic Acids Res.* 1996; 24:141-6.
15. Elzagheid A, Kuopio T, Ilmen M, Collan Y. Prognostication of invasive ductal breast cancer by quantification of E-cadherin immunostaining: the methodology and clinical relevance. *Histopathology.* 2002;41:127-33.
16. Lipponen P, Collan Y. Simple quantitation of immunohistochemical staining positivity in microscopy. *Acta Stereol* 1992; 11:125-32
17. Pegram MD, Pietras R, Bajamonde A, Klein P, Fyfe G. Targeted therapy: wave of the future. *J Clin Oncol* 2005; 23:1776-81.
18. Wang X, Zhang S, MacLennan G T, et al. Epidermal Growth Factor Receptor Protein Expression and Gene Amplification in Small Cell Carcinoma of the Urinary Bladder. *Clin Cancer Res.* 2007;13:953-7
19. Guo CC, Gomez E, Tamboli P, et al. Squamous cell carcinoma of the urinary bladder: a clinicopathologic and immunohistochemical study of 16 cases. *Hum Pathol.* 2009.